



OPEN ACCESS

Impact of somato-cognitive coordination therapy on activities of daily living in a patient with Huntington's disease

Keito Shinmoto ,^{1,2} Yuki Torikai,³ Masahiko Hara^{3,4}

¹Department of Neurology and Clinical Rehabilitation, mediVR Rehabilitation Center Tokyo, Chuo-ku, Tokyo, Japan
²Office of Research and Academia-Government-Community Collaboration, Headquarters for Open Innovation, Department of Academia-Government-Industry Collaboration, Biodesign Division, Hiroshima University, Hiroshima, Japan
³Department of Neurology and Clinical Rehabilitation, mediVR Rehabilitation Center Osaka, Toyonaka, Osaka, Japan
⁴Centre for Community-Based Healthcare Research and Education, Shimane University Faculty of Medicine, Izumo, Shimane, Japan

Correspondence to

Dr Keito Shinmoto;
 shinmoto.keito@medivr.jp

Accepted 7 November 2024

SUMMARY

Huntington's disease (HD) causes progressive neurodegeneration, impairing activities of daily living (ADL). Treatment focuses primarily on symptomatic relief through multidisciplinary approaches. This case report examines the impact of somato-cognitive coordination therapy (SCCT) on ADL in a patient with HD. A woman in her 40s with early-stage HD underwent 22 SCCT sessions using the mediVR KAGURA (mediVR), a virtual reality technology-based medical device over 20 months. Her total functional capacity rating scale improved from 10 to 11 and her Barthel Index improved from 90 to 100 within 3 months, allowing her to continue working. These improvements were sustained for 17 months. Objective measures like the single-leg stance test showed consistent progress. Improved cognitive function and psychiatric well-being were also suggested by the Trail Making Test and a return to hobbies like hiking. SCCT may have the potential to improve ADL and could complement multidisciplinary care strategy for HD patients.

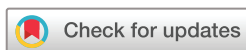BACKGROUND

Huntington's disease (HD) is a rare, autosomal dominant disorder with progressive neurodegeneration, causing various motor, cognitive and psychiatric impairments.^{1,2} Among motor symptoms, impaired voluntary control manifests as gait disturbance, hand dysfunction and speech problems. In the cognitive domain, a wide variety of abilities, such as executive function and processing speed, are diminished. Psychiatric disturbances such as depression and anxiety are also common. These problems significantly affect the quality of life, often leading to the loss of employment and the need for job modifications even in the early stages.^{1,2} Despite exploring various pharmacological and non-pharmacological interventions, the treatment of HD primarily aims at symptomatic relief through multidisciplinary approaches.¹⁻³ In this context, we report our experience of applying somato-cognitive coordination therapy (SCCT) to a patient with HD.⁴ SCCT is a therapeutic approach using virtual reality (VR) technologies (figure 1 and online supplemental video 1) which has recently been explored in Parkinson's disease.⁴⁻⁸ This case report describes a patient in the early stages of HD who experienced significant improvements in activities of daily living (ADL) following the SCCT intervention.

Figure 1 shows schematic illustrations and patient interaction during SCCT sessions. Panels A and B contrast the left-hand reaching movement of a healthy individual with that of a patient, highlighting discrepancies in motor function. In SCCT sessions, patients perform reaching tasks with alternating hands while seated. A unique feature of the therapy is the provocation of AL, unintended joint movements during intended actions, which is made apparent in the specially designed immersive virtual reality environment that does not use body avatars. This provocation helps to identify and target AL for therapeutic intervention. Panel C shows the patient's initial reaching attempt towards a target at a 45-degree angle to the left, where AL is evident, such as involuntary adduction of the left upper limb, left trunk flexion and right shoulder elevation, reflecting the entangled somato-cognitive action network in our viewpoints. Such movements can challenge the patient's ability to maintain visual focus on the target. Interventions focus on reducing AL by using tactile and verbal cues to guide correct movements by a certified therapist. As a result, tasks are tailored to each patient's specific abilities. Panel




Figure 1 mediVR KAGURA-Guided Somato-Cognitive Coordination Therapy in Huntington's disease.



© BMJ Publishing Group Limited 2024. Re-use permitted under CC BY-NC. No commercial re-use. See rights and permissions. Published by BMJ Group.

To cite: Shinmoto K, Torikai Y, Hara M. *BMJ Case Rep* 2024;**17**:e262695. doi:10.1136/bcr-2024-262695

Case report

D shows some reduction in AL over the course of the session, particularly in the improved, although slow, reaching ability of the left arm and the reduced trunk flexion and right shoulder elevation. However, AL is still present to some degree in the right arm. Changes in these movements and interventions can be further explored in online supplemental video 1.

CASE PRESENTATION

A woman in her 40s with a strong familial history of HD, including her mother, maternal uncle and grandfather, was referred to our institution for SCCT due to progressive motor symptoms that began approximately 2 years ago. Genetic testing at an advanced medical facility 3 months ago confirmed HD through a heterozygous CAG repeat expansion, with a repeat length of 44. Her treatment regimen for sleep disturbances and anxiety included zolpidem (10 mg/day) and ethyl loflazepate (1 mg/day), respectively. Both medications were continued throughout the treatment period and were not discontinued. She also underwent a brief, unsuccessful trial of tetrabenazine (12.5 mg/day) for motor symptoms, discontinued due to side effects of depressive symptoms. Prior to her presentation, the patient had not received rehabilitation services at any other facility. At her initial presentation, her early-stage HD was characterised by a Total Functional Capacity (TFC) Rating Scale of 10 and a Barthel Index (BI) of 90 indicating mild disability. Gait disturbances hindered her ability to hike, a cherished hobby, and it limited her to one-finger typing at work. Involuntary biting of her tongue and inner mouth during conversations further impacted her clerical job, leading her to consider resigning to focus on treatment. Initial evaluations revealed challenges with balance, mobility and upper extremity function.

TREATMENT

A certified SCCT interventionist introduced the therapy using the mediVR KAGURA (mediVR, Inc., Toyonaka, Japan), a VR

technology-based medical device. In SCCT sessions, patients perform reaching tasks with alternating hands while seated (figure 1 and online supplemental video 1). Each SCCT session lasted approximately 30 min, employing 18 patented technologies designed to improve motor control through visualisation of articular linkage (AL), addressing the complex and intertwined somato-cognitive action network (SCAN).^{4,9} A unique feature of the therapy is the provocation of AL, unintended joint movements during intended actions, which is made apparent in the specially designed immersive VR environment that does not use body avatars. Interventions focus on reducing AL akin to untangling the complex and intertwined puppet strings by using tactile and verbal cues to guide correct movements by a certified therapist. Tasks are tailored to each patient's specific abilities.⁴

OUTCOME AND FOLLOW-UP

Over the course of 20 months, the patient underwent 22 SCCT sessions, generally conducted once a month but adjusted according to her work schedule, resulting in significant improvements without any side effects or negative experiences (figure 2). For example, she reported substantial enhancements that allowed her to resume hiking, initially on trails up to 300 m at 3 months, and eventually climbing mountains up to 969 m at 9 months. Improvements in typing and speech-related issues within the first 3 months led her to reconsider her decision to retire, during which her TFC improved to 11 and her BI reached 100. While subjective recovery plateaued at 3 months post-SCCT, objective measures improved consistently throughout the treatment. In the single-leg stance test, initial scores of 4.0/2.3 s (right/left leg) improved to 34.0/23.8 s at 19 months. The Timed Up and Go test at maximum effort showed progress from 7.9 s to 6.1 s. The pegboard test for the dominant right hand improved from 44.0 s at initial to 35.2 s over 20 months (online supplemental video 2). 9 months into the therapy, colleagues and friends noticed her faster reaction time, prompting an evaluation with the

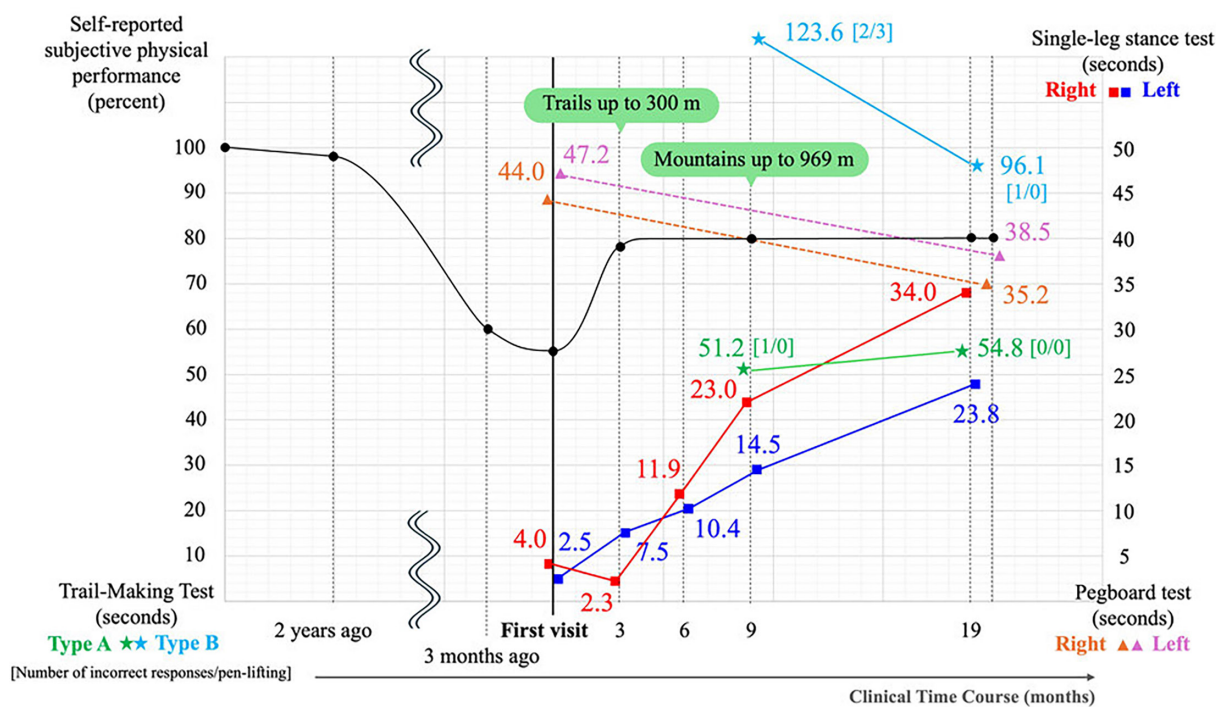


Figure 2 Subjective and objective measures over 20 months of Huntington's disease treatment.

Trail Making Test (TMT).¹⁰ Although it was not continuously monitored, the TMT-B showed notable improvement with the completion time reduced from 123.6 s at 9 months to 96.1 s at 19 months, incorrect responses decreased from 2 to 1 and pen-lifting errors reduced from 3 to 0 (online supplemental video 3). During this time, her medication regimen remained unchanged, and no treatments other than SCCT were administered.

Figure 2 illustrates the clinical progression and response to treatment over a 20-month period in a patient with HD. The left y-axis represents self-reported subjective physical performance, denoted by black circles, showing a decline from 100% over 2 years to 60% at genetic diagnosis (3 months prior) and further to 55% at initial assessment at our institution. After treatment, a significant recovery to nearly 80% is observed, with a subsequent plateau in self-reported physical function. In addition, TMT scores are plotted, with type A shown as green stars and type B as light blue stars, and show significant improvements in TMT-B from 123.6 s to 96.1 s, incorrect responses from 2 to 1 and pen-lifting errors from 3 to 0. The right y-axis details objective measures, including the single-leg stance test (right leg in red squares, left leg in blue squares) and the pegboard test of hand function (right hand in orange triangles, left hand in pink triangles), showing continued improvements in balance and dexterity despite a plateau in subjective symptoms. A detailed visual assessment is shown in online supplemental video 2.

DISCUSSION

This case report highlights a patient with HD demonstrating substantial improvements in ADL and a spectrum of motor symptoms following SCCT, with additional benefits observed in cognitive and possibly psychiatric domains. The novelty of SCCT lies in its conceptualisation of addressing the intertwined SCAN, providing a unified approach to the treatment of multiple motor symptoms.⁵ This conceptualisation suggests potential benefits, as indicated by preliminary results from a feasibility study in advanced severe Parkinson's disease, where seated reaching exercises showed statistically significant improvements in gait and upper limb metrics.⁴ The simultaneous improvement in balance, gait, upper limb and speech function in our patient suggests that targeting SCAN can effectively improve motor coordination, consistent with the underlying concept of SCCT. We observed that marginal changes in overall functional capacity like TFC and BI did not entirely align with specific functional assessments or the subjective patient reports. Given the nature of a single case report, it is difficult to determine whether these changes are statistically significant. However, this experience reminds us of the clinical importance of adopting a multifaceted approach to patient assessment, recognising that different measures may capture different aspects of patient progress. Cognitive improvements, although not conclusively monitored, suggest the potential for better control of body movements to free up cognitive resources for situational judgement and other cognitive tasks. This suggests that improving physical coordination through SCCT may indirectly benefit cognitive functions. In addition to improvements in motor and cognitive domains, this case indicates potential psychiatric benefits, as evidenced by our patient's return to hobbies such as hiking and continued work, highlighting how physical and activity enhancements may improve psychiatric well-being. There are several limitations that warrant mention. For example, questions regarding the placebo effect, differentiation from existing therapies and cost-effectiveness cannot be fully addressed at this stage, as this is a single case report. Traditional therapies may provide similar benefits,

although the SCCT in this case demonstrated its potential to address multiple symptoms with fewer sessions, which may offer some practical advantages. This 20-month therapy was designed as proof of concept. We plan to use these results to work with patient organisations and healthcare providers to develop future clinical research and explore the potential of SCCT to improve the lives of more people with HD.

Patient's perspective

Just by sitting and completing a simple game, I have seen significant improvements in daily activities such as cooking, washing dishes, hanging and folding laundry, and work-related tasks like typing on a computer keyboard or using a calculator. There has been no pain or side effects, and various benefits have been achieved. I believe this treatment could be beneficial for other patients with Huntington's disease as well.

Learning points

- ▶ Somato-cognitive coordination therapy (SCCT) successfully enhanced activities of daily living in a patient with early-stage Huntington's disease (HD).
- ▶ The benefits of SCCT were maintained over a 20-month period with therapy sessions conducted approximately once a month.
- ▶ SCCT consistently improved motor functions, cognitive abilities and psychiatric well-being.
- ▶ SCCT may serve as a complementary approach to multidisciplinary care strategy for HD patients.

Contributors KS is the guarantor responsible for the overall content. The following authors were responsible for drafting of the text, sourcing and editing of clinical images, investigation results, drawing original diagrams and algorithms, and critical revision for important intellectual content: KS, YT, MH. The following authors gave final approval of the manuscript: KS, YT, MH.

Funding The authors have not declared a specific grant for this research from any funding agency in the public, commercial or not-for-profit sectors.

Competing interests mediVR KAGURA is a medical device of mediVR, Inc. MH is a director and holds private equity in mediVR, Inc. KS and YT are full-time employees of mediVR, Inc. mediVR, Inc. runs the mediVR Rehabilitation Center. MH is a director and holds private equity in mediVR, Inc. KS and YT are full-time employees of mediVR, Inc. The lead clinician has ensured the veracity of all author declarations of conflict of interest and author disclosures.

Patient consent for publication Consent obtained directly from patient(s).

Provenance and peer review Not commissioned; externally peer reviewed.

Open access This is an open access article distributed in accordance with the Creative Commons Attribution Non Commercial (CC BY-NC 4.0) license, which permits others to distribute, remix, adapt, build upon this work non-commercially, and license their derivative works on different terms, provided the original work is properly cited and the use is non-commercial. See: <http://creativecommons.org/licenses/by-nc/4.0/>.

Case reports provide a valuable learning resource for the scientific community and can indicate areas of interest for future research. They should not be used in isolation to guide treatment choices or public health policy.

ORCID iD

Keito Shinmoto <http://orcid.org/0000-0002-5353-2882>

REFERENCES

- 1 McColgan P, Tabrizi SJ. Huntington's disease: a clinical review. *Eur J Neurol* 2018;25:24–34.
- 2 Stoker TB, Mason SL, Greenland JC, et al. Huntington's disease: diagnosis and management. *Pract Neurol* 2022;22:32–41.

- 3 Tabrizi SJ, Estevez-Fraga C, Roon-Mom WMC, *et al.* Potential disease-modifying therapies for Huntington's disease: lessons learned and future opportunities. *Lancet Neurol* 2022;21:645–58.
- 4 Hara M, Murakawa Y, Wagatsuma T, *et al.* Feasibility of somato-cognitive coordination therapy using virtual reality for patients with advanced severe Parkinson's disease. *J Parkinsons Dis* 2024;14:895–8.
- 5 Takimoto K, Omon K, Murakawa Y, *et al.* Case of cerebellar ataxia successfully treated by virtual reality-guided rehabilitation. *BMJ Case Rep* 2021;14:e242287.
- 6 Michibata A, Haraguchi M, Murakawa Y, *et al.* Electrical stimulation and virtual reality-guided balance training for managing paraplegia and trunk dysfunction due to spinal cord infarction. *BMJ Case Rep* 2022;15:e244091.
- 7 Omon K, Hara M, Ishikawa H. Virtual Reality-guided, Dual-task, Body Trunk Balance Training in the Sitting Position Improved Walking Ability without Improving Leg Strength. *Prog Rehabil Med* 2019;4:20190011.
- 8 Yamaguchi T, Miwa T, Tamura K, *et al.* Temporal virtual reality-guided, dual-task, body trunk-balance training in a sitting position improves persistent postural-perceptual dizziness: proof of concept. *J Neuroeng Rehabil* 2022;19:92.
- 9 Gordon EM, Chauvin RJ, Van AN, *et al.* A somato-cognitive action network alternates with effector regions in motor cortex. *Nature New Biol* 2023;617:351–9.
- 10 Bowie CR, Harvey PD. Administration and interpretation of the Trail Making Test. *Nat Protoc* 2006;1:2277–81.

Copyright 2023 BMJ Publishing Group. All rights reserved. For permission to reuse any of this content visit <https://www.bmj.com/company/products-services/rights-and-licensing/permissions/>
BMJ Case Report Fellows may re-use this article for personal use and teaching without any further permission.

Become a Fellow of BMJ Case Reports today and you can:

- ▶ Submit as many cases as you like
- ▶ Enjoy fast sympathetic peer review and rapid publication of accepted articles
- ▶ Access all the published articles
- ▶ Re-use any of the published material for personal use and teaching without further permission

Customer Service

If you have any further queries about your subscription, please contact our customer services team on +44 (0) 207111 1105 or via email at support@bmj.com.

Visit casereports.bmj.com for more articles like this and to become a Fellow